

Treatment success in six months

DR ANOOP MAINI presents a case study, showing how Six Month Smiles corrected the teeth of a previously self-conscious 24-year-old woman...

THERE has been a major movement in the UK towards dentists providing short-term orthodontics to assist them with cosmetic dentistry. Six Month Smiles is the largest short-term orthodontic system in the UK and is designed exclusively for general dentists.

There are more than a thousand trained dentists working in the UK now providing Six Month Smiles. One of the main driving forces behind this move has been a change in philosophy that means dentists are now seeking to provide quality cosmetic solutions that are also minimally invasive and preserve as much tooth structure as possible. Another key factor has been the growing demand from patients who are seeking quicker fixes to their teeth, and don't want to go down the traditional restorative mode to have their teeth prepared for crowns or veneers, and similarly aren't prepared to go on much longer courses of orthodontic treatment that, in many cases, can take 16 months to two years.

Case presentation

This young lady is a 24-year-old nursery teacher. She had braces in the past as a teenager, but her teeth began to relapse over the last few years. As such, she had become very self-conscious about

her smile, and the children at her nursery were remarking on them. She declined comprehensive orthodontics, even though she would have received the ideal result, because her treatment may take more than a year. She instead opted for Six Month Smiles as she wanted to complete the treatment quickly, and the six-month time frame was more than acceptable to her.

Six Month Smiles' ability to complete treatment in this time frame comes as a result of using proven principles of straight wire orthodontics to level and align teeth. The reason for the shorter time frame is that we are focusing on aligning the teeth that show in the smile. The advantage of Six Month Smiles over clear aligner systems is that Six Month Smiles can move teeth far more efficiently, and is generally two to three times faster than clear aligners. Clear aligners try to move teeth by "squeezing" the teeth into position, which is a very inefficient way of moving teeth. Also, clear aligners struggle with certain types of tooth movements, particularly rotations and extrusions, whereas with Six Month Smiles, these movements are well within the system's capabilities and the result is also very predictable.

The laboratory charges for Six Month

Smiles vary from £250 to £350 per case.

Assessment and treatment

When the patient arrived for initial assessment, she had no active caries, she had good periodontal health, her TMJ was asymptomatic, and there were no signs of parafunctional active teeth. She had dental class 1 occlusion, with moderate crowding in her lower anterior teeth and mild crowding in her upper anterior teeth. In the lower arch, she also had a lower incisor that was in-standing.

By using an Open Coil Spring (OCS) technique, and progressive interproximal reduction across the arch, combined with the rounding out of the anterior segment by the Lucid-Lok NiTi wires, the crowding was relieved (Figure 5).

Colleagues should note that Six Month Smiles is not a replacement for comprehensive orthodontics, but it is useful for patients who choose not to go with the comprehensive option, provided the patient's chief concerns are not related to the anterior-posterior relationship, which means Six Month Smiles will not attempt to correct, such as overjet in a dental class 2 patient.

With all orthodontic treatment, it is important – especially in adults – to avoid relapse. As such, the patient should always be given retainers. In this case, we used bonded lingual retainers inter-canine, in the upper and lower arches (Figures 9 and 10), and the patient was advised that this is a lifetime commitment as part of the consent process.

Figure 13: Post-operative full face



Reader enquiry:

About the author

Dr Anoop Maini is Chair of the BACD Education Committee. He qualified from King's College in 1992 and has worked in private practice since 1993 in London's West End.

Dr Maini has a special interest in advanced cosmetic and implant dentistry, having studied extensively in the USA and the UK. He currently serves as the Vice President of the British Academy of Cosmetic Dentistry and is a founding member of the British Society of Cosmetic Orthodontics.

He is a clinical instructor for Six Month Smiles.

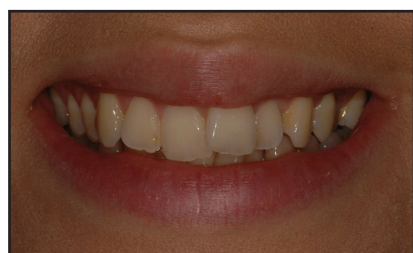

Figure 1: Smile before treatment

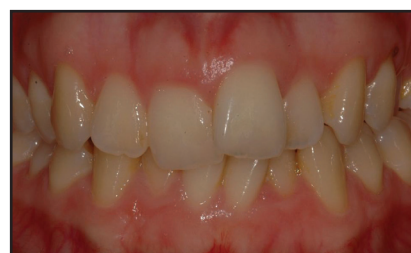

Figure 2: Patient's retracted smile before treatment

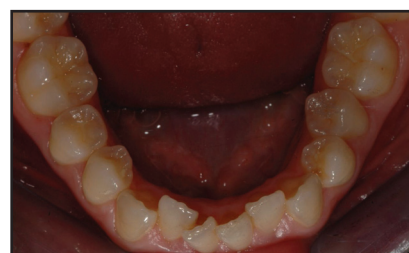

Figure 3: Lower arch before treatment

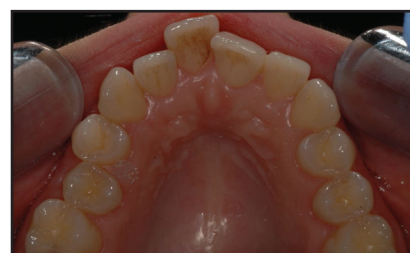

Figure 4: Upper arch before treatment

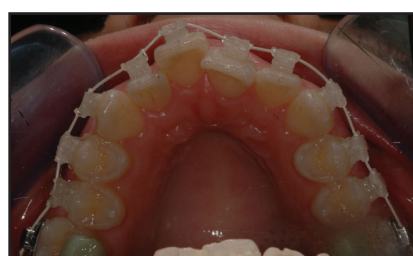

Figure 5: Upper arch after placement of Lucid-Lok brackets and NiTi wires

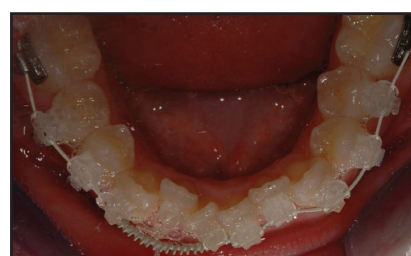

Figure 6: Braces on appointment. Open Coil Spring to create space for in-standing incisor

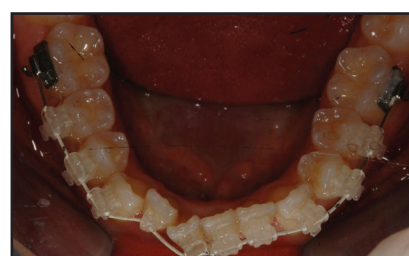

Figure 7: One month later, enough space is created by the coil, mild strip IPR and rounding out of the arch for the incisor to be directly engaged and brought into the arch

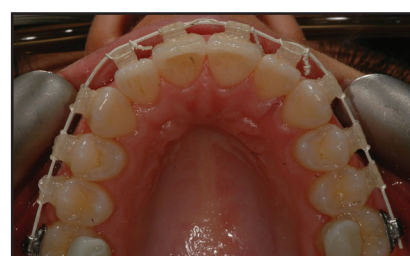

Figure 8: Upper arch after five months

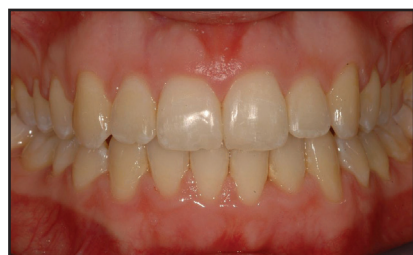

Figure 9: Post-operative retracted smile

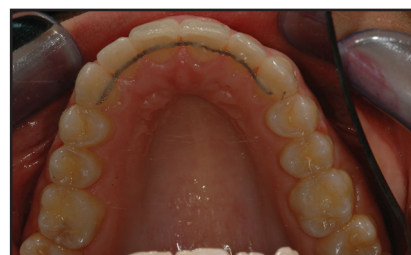

Figure 10: Post-operative upper occlusal view. Notice how the arch has rounded out. A bonded lingual retainer is placed for retention

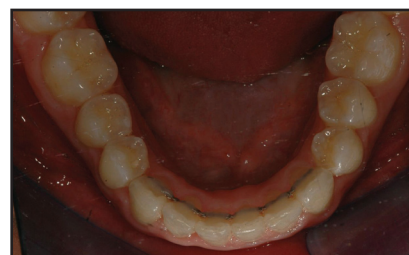


Figure 11: Bonded lingual retainer (lower)

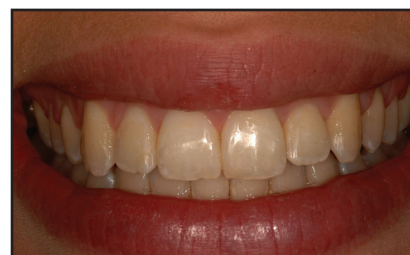

Figure 12: Post-operative smile